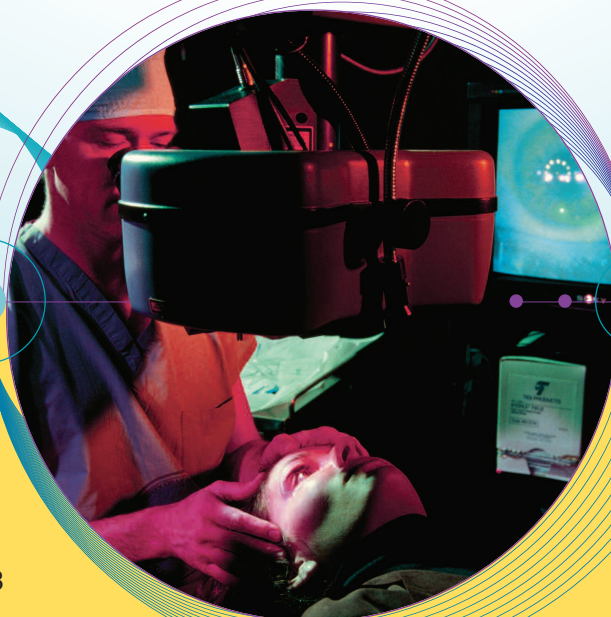

VISIT [HTTPS://WWW.TINYURL.COM/CATARACTANDREFRACTIVECASES](https://www.tinyurl.com/cataractandrefractivecases)
FOR ONLINE TESTING AND INSTANT CME CERTIFICATE

CME MONOGRAPH

A DAY IN THE LIFE OF AN OPHTHALMIC SURGEON

Cataract and Refractive Cases in Patients With Comorbidities



Original Release: May 1, 2018
Expiration: May 31, 2019

FACULTY

Eric D. Donnenfeld, MD (Chair)
Robert J. Noecker, MD, MBA
Tal Raviv, MD
Elizabeth Yeu, MD

This continuing medical education activity is jointly provided by **New York Eye and Ear Infirmary of Mount Sinai** and MedEdicus LLC.



MedEdicus
LLC

This continuing medical education activity is supported through an unrestricted educational grant from Bausch & Lomb Incorporated.

Distributed with **EyeNet**

FACULTY

Eric D. Donnenfeld, MD (Chair)

Clinical Professor of Ophthalmology
New York University
Langone Medical Center
New York, New York
Founding Partner
Ophthalmic Consultants
of Long Island and Connecticut
Garden City, New York

Robert J. Noecker, MD, MBA

Director of Glaucoma
Ophthalmic Consultants of Connecticut
Fairfield, Connecticut
Assistant Clinical Professor of Ophthalmology
Yale University School of Medicine
New Haven, Connecticut
Professor of Surgery
Frank H. Netter MD School of Medicine
Quinnipiac University
North Haven, Connecticut

Tal Raviv, MD

Associate Clinical Professor of Ophthalmology
Icahn School of Medicine at Mount Sinai
Founder and Medical Director
Eye Center of New York
New York, New York

Elizabeth Yeu, MD

Assistant Professor of Ophthalmology
Eastern Virginia Medical School
Corneal, Cataract, and Refractive Surgeon
Partner
Virginia Eye Consultants
Norfolk, Virginia

CME REVIEWER FOR NEW YORK EYE AND EAR INFIRMARY OF MOUNT SINAI

Priti Batta, MD

Assistant Professor of Ophthalmology
Icahn School of Medicine at Mount Sinai
Director, Medical Student Education
Assistant Director, Comprehensive
Ophthalmology Service
New York Eye and Ear Infirmary
of Mount Sinai
New York, New York

LEARNING METHOD AND MEDIUM

This educational activity consists of a supplement and ten (10) study questions. The participant should, in order, read the learning objectives contained at the beginning of this supplement, read the supplement, answer all questions in the post test, and complete the Activity Evaluation/Credit Request form. To receive credit for this activity, please follow the instructions provided on the post test and Activity Evaluation/Credit Request form. This educational activity should take a maximum of 1.5 hours to complete.

CONTENT SOURCE

This continuing medical education (CME) activity captures content from a CME symposium held on November 12, 2017, in New Orleans, Louisiana.

ACTIVITY DESCRIPTION

This program will provide a case-based learning experience on preoperative, perioperative, and postoperative factors for success in refractive cataract surgery in a variety of patients with comorbidities. Topics include addressing preoperative ocular surface disorders, intraocular lens selection, intraoperative considerations, postoperative infection, and inflammation control.

TARGET AUDIENCE

This educational activity is intended for ophthalmologists.

LEARNING OBJECTIVES

Upon completion of this activity, participants will be better able to:

- Consider ocular surface conditions preoperatively in patients undergoing cataract surgery
- Describe appropriate medication regimens for inflammation and infection control in patients undergoing cataract surgery
- Review factors for optimal IOL selection
- Appraise femtosecond cataract surgery technology vs conventional cataract surgery technology

ACCREDITATION STATEMENT

This activity has been planned and implemented in accordance with the accreditation requirements and policies of the Accreditation Council for Continuing Medical Education (ACCME) through the joint providership of **New York Eye and Ear Infirmary of Mount Sinai** and MedEdicus LLC. The **New York Eye and Ear Infirmary of Mount Sinai** is accredited by the ACCME to provide continuing medical education for physicians.



In July 2013, the Accreditation Council for Continuing Medical Education (ACCME) awarded New York Eye and Ear Infirmary of Mount Sinai "Accreditation with Commendation," for six years as a provider of continuing medical education for physicians, the highest accreditation status awarded by the ACCME.

AMA CREDIT DESIGNATION STATEMENT

The **New York Eye and Ear Infirmary of Mount Sinai** designates this enduring material for a maximum of 1.5 *AMA PRA Category 1 Credits™*. Physicians should claim only the credit commensurate with the extent of their participation in the activity.

GRANTOR STATEMENT

This continuing medical education activity is supported through an unrestricted educational grant from Bausch & Lomb Incorporated.

DISCLOSURE POLICY STATEMENT

It is the policy of **New York Eye and Ear Infirmary of Mount Sinai** that the faculty and anyone in a position to control activity content disclose any real or apparent conflicts of interest relating to the topics of this educational activity, and also disclose

discussions of unlabeled/unapproved uses of drugs or devices during their presentation(s). **New York Eye and Ear Infirmary of Mount Sinai** has established policies in place that will identify and resolve all conflicts of interest prior to this educational activity. Full disclosure of faculty/planners and their commercial relationships, if any, follows.

DISCLOSURES

Eric D. Donnenfeld, MD, had a financial agreement or affiliation during the past year with the following commercial interests in the form of *Consultant/Advisory Board*: Abbott Medical Optics; AcuFocus, Inc; Alcon; Allergan; AqueSys, Inc; Avedro, Inc; Bausch & Lomb Incorporated; Beaver-Visitec International; ELENZA, Inc; ForSight; Glaukos Corporation; Icon Bioscience, Inc; Kala Pharmaceuticals; Katena Products, Inc; LacriScience; LensGen; Mati Therapeutics, Inc; Merck & Co., Inc; Mimetogen Pharmaceuticals, Inc; NovaBay Pharmaceuticals, Inc; Novaliq GmbH Germany; OcuHub LLC; Odyssey Medical, Inc; Omega Ophthalmics; Omeros Corporation; Oyster Point Therapeutics; Pfizer Inc; PogoTec; PRN; Rapid Pathogen Screening, Inc; Shire; Strathspey Crown; Sun; TearLab Corporation; TrueVision; Versant Ventures; and Zeiss; *Ownership Interest (Stock options, or other holdings, excluding diversified mutual funds)*: AqueSys, Inc; Autofocus; Avedro, Inc; ELENZA, Inc; Glaukos Corporation; LacriScience; LensGen; Mati Therapeutics, Inc; Mimetogen Pharmaceuticals; NovaBay Pharmaceuticals, Inc; OcuHub LLC; PogoTec; Rapid Pathogen Screening, Inc; SARcode Bioscience, Inc; Strathspey Crown; TearLab Corporation; TrueVision; Versant Ventures; and Visionary Ventures, LLC.

Robert J. Noecker, MD, MBA, had a financial agreement or affiliation during the past year with the following commercial interests in the form of *Consultant/Advisory Board*: Aerie Pharmaceuticals, Inc; Alcon; Allergan; Beaver-Visitec International; Diopsys, Inc; Ethis; Glaukos Corporation; InnFocus Inc; Inotek Pharmaceuticals Corporation; IRIDEX Corporation; Novartis AG; Ocular Therapeutix, Inc; Omeros Corporation; Polyactiva Pty Ltd; Santen Pharmaceutical Co, Ltd; Shire; SOLX, Inc; and Sun; *Contracted Research*: AqueSys, Inc; Glaukos Corporation; and InnFocus Inc; *Honoraria from promotional, advertising or non-CME services received directly from commercial interests or their Agents (eg, Speakers Bureaus)*: Allergan; Beaver-Visitec International; Diopsys, Inc; IRIDEX Corporation; Novartis AG; and Quantel; *Ownership Interest (Stock options, or other holdings, excluding diversified mutual funds)*: ISP; Ocular Therapeutix, Inc; and Tula Medical.

Tal Raviv, MD, had a financial agreement or affiliation during the past year with the following commercial interests in the form of *Consultant/Advisory Board*: Glaukos Corporation; i-Optics; Johnson & Johnson Vision Care, Inc; and Ocular Therapeutix, Inc; *Honoraria from promotional, advertising or non-CME services received directly from commercial interests or their Agents (eg, Speakers Bureaus)*: Shire.

Elizabeth Yeu, MD, had a financial agreement or affiliation during the past year with the following commercial interests in the form of *Consultant/Advisory Board*: Abbott Medical Optics; Alcon; Bausch & Lomb Incorporated; i-Optics; Ocular Science; Ocular Therapeutix, Inc; Shire; TearLab Corporation; TearScience; and Valeant; *Honoraria from promotional, advertising or non-CME services received directly from commercial interests or their Agents (eg, Speakers Bureaus)*: Abbott Medical Optics; Alcon; Allergan; Rapid Pathogen Screening, Inc; and TearLab Corporation; *Ownership Interest (Stock options, or other holdings, excluding diversified mutual funds)*: Modernizing Medicine; and Strathspey Crown.

SPONSORED SUPPLEMENT

NEW YORK EYE AND EAR INFIRMARY OF MOUNT SINAI PEER REVIEW DISCLOSURE

Priti Batta, MD, has no relevant commercial relationships to disclose.

EDITORIAL SUPPORT DISCLOSURES

Cheryl Guttman Krader; Diane McArdle, PhD; Cynthia Tornallyay, RD, MBA, CHCP; Kimberly Corbin, CHCP; Barbara Auel; and Michelle Ong have no relevant commercial relationships to disclose.

DISCLOSURE ATTESTATION

The contributing physicians listed above have attested to the following:

- 1) that the relationships/affiliations noted will not bias or otherwise influence their involvement in this activity;
- 2) that practice recommendations given relevant to the companies with whom they have relationships/affiliations will be supported by the best available evidence or, absent evidence, will be consistent with generally accepted medical practice; and
- 3) that all reasonable clinical alternatives will be discussed when making practice recommendations.

OFF-LABEL DISCUSSION

This CME activity includes discussion of unlabeled and/or investigative uses of drugs. Please refer to the official prescribing information for each drug discussed in this activity for FDA-approved dosing, indications, and warnings.

FOR DIGITAL EDITIONS

System Requirements:

If you are viewing this activity online, please ensure the computer you are using meets the following requirements:

- **Operating System:** Windows or Macintosh
- **Media Viewing Requirements:** Flash Player or Adobe Reader
- **Supported Browsers:** Microsoft Internet Explorer, Firefox, Google Chrome, Safari, and Opera
- **A good Internet connection**

NEW YORK EYE AND EAR INFIRMARY OF MOUNT SINAI PRIVACY & CONFIDENTIALITY POLICIES

<http://www.nyee.edu/health-professionals/cme/enduring-activities>

CME PROVIDER CONTACT INFORMATION

For questions about this activity, call 212-870-8127.

TO OBTAIN AMA PRA CATEGORY 1 CREDIT™

To obtain AMA PRA Category 1 Credit™ for this activity, read the material in its entirety and consult referenced sources as necessary. Please take this post test and evaluation online by going to <https://tinyurl.com/cataractandrefractivecases>. Upon passing, you will receive your certificate immediately. You must score 70% or higher to receive credit for this activity, and may take the test up to 2 times. Upon registering and successfully completing the post test, your certificate will be made available online and you can print it or file it. There are no fees for participating in and receiving CME credit for this activity.

DISCLAIMER

The views and opinions expressed in this educational activity are those of the faculty and do not necessarily represent the views of New York Eye and Ear Infirmary of Mount Sinai, MedEdicus LLC, Bausch & Lomb Incorporated, EyeNet, or the American Academy of Ophthalmology.

A DAY IN THE LIFE OF AN OPHTHALMIC SURGEON

Cataract and Refractive Cases in Patients With Comorbidities

INTRODUCTION

Advances in intraocular lens (IOL) technology, surgical techniques, and medications are providing benefits to patients needing cataract surgery, but decisions about their use need to be individualized, taking into account patient goals and any ocular comorbidity. In this activity, expert faculty discuss preoperative, intraoperative, and postoperative considerations for optimizing surgical success and patient satisfaction in a series of challenging cases.

CASE 1: A PATIENT WITH KERATOCONUS

From the Files of Tal Raviv, MD

A 70-year-old male presents for cataract surgery in his right eye. Findings on examination in the right eye are refraction +1.00 -2.00 × 33; best corrected visual acuity (BCVA) 20/60; keratometry 51.66/56.64 at 142; significant superficial punctate keratitis; and meibomian gland inspissation. He has 3+ nuclear sclerotic (NS) cataract OU. Topography shows irregularity in both eyes, but there are also significant areas of dropout in the images, particularly in the superior and inferonasal regions (**Figure 1**).

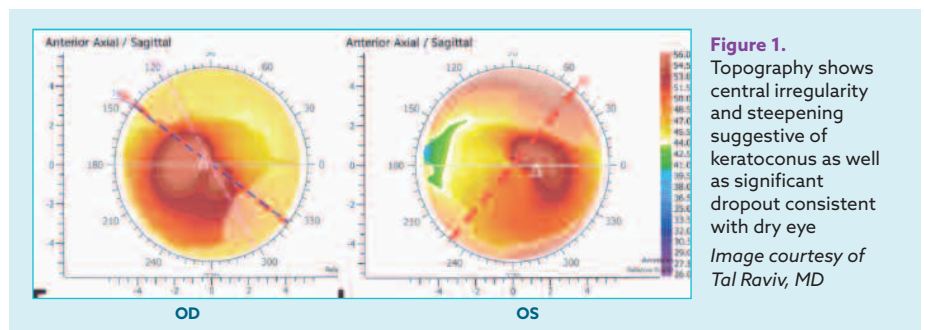


Figure 1. Topography shows central irregularity and steepening suggestive of keratoconus as well as significant dropout consistent with dry eye. Image courtesy of Tal Raviv, MD

Dr Raviv: The topographic pattern in this patient is consistent with irregular nonorthogonal astigmatism, but his clinical examination and dropout on topography indicate he has dry eye disease (DED).

How common is DED in the cataract surgery population?

Dr Yeu: In the Prospective Health Assessment of Cataract Patients' Ocular Surface study, 77% of patients had moderately severe DED with positive corneal staining and 50% had central corneal staining, but only 22% had a prior diagnosis of DED.¹

Dr Raviv: Why is it important to treat DED in patients needing cataract surgery?

Dr Noecker: Dry eye disease affects the accuracy of the measurements that are used to plan cataract surgery, including keratometry, topography, and aberrometry.^{2,3} It also affects visual acuity, visual quality, and patient comfort, and it can be exacerbated by cataract surgery.^{4,7} Therefore, DED affects refractive and functional outcomes and patient satisfaction postoperatively.⁷

Dr Raviv: Dry eye disease may partly or even mostly explain reduced visual acuity in some patients with cataract, and patients who did not recognize they had the problem preoperatively may become aware of it after their procedure. Therefore, it is important to educate them about DED and its consequences.

“Dry eye disease affects the accuracy of the measurements that are used to plan cataract surgery, including keratometry, topography, and aberrometry. It also affects visual acuity, visual quality, and patient comfort, and it can be exacerbated by cataract surgery.”

—Robert J. Noecker, MD, MBA

Dr. Donnenfeld, what do you tell patients who have high expectations for good uncorrected vision after cataract surgery who need treatment for DED?

Dr. Donnenfeld: I tell them that we have to rehabilitate the ocular surface before planning surgery because it is impossible to have a premium result without a premium tear film.

Many patients on whom we operate are sent to us by other ophthalmologists or optometrists; it is important to educate these referring doctors so that they identify and manage the DED before sending patients for a cataract surgery evaluation. It may be several weeks before patients are able to get an appointment for the cataract consultation, and their DED can be treated in the meantime.

“It is important to educate referring ophthalmologists and optometrists that they should identify and manage DED before sending patients for a cataract surgery evaluation. It may be several weeks before patients are able to get an appointment for the cataract consultation, and their DED can be treated in the meantime.”

—Eric D. Donnenfeld, MD

Dr. Yeu: I agree. Patients who come for a cataract evaluation and are told that they need to come back for another examination before they can be scheduled for surgery may be very disappointed and lose trust in their primary eye care provider, who failed to tell them about their DED.

Dr. Donnenfeld: Once patients know they need cataract surgery, they are likely eager to have it done. To provide rapid rehabilitation of the ocular surface, I use a topical corticosteroid to treat DED in these patients.^{8,9}

It is my impression that corticosteroids are underused for this purpose because physicians are concerned about side effects. I use loteprednol etabonate gel, 0.5%, because loteprednol has a low potential for causing intraocular pressure (IOP) elevation and cataract.¹⁰ Fluorometholone is my second choice, but it is less potent than loteprednol as an anti-inflammatory agent.¹¹

Dr. Raviv: I agree with that approach. It is also important to think about ongoing care because DED can be a chronic condition.

Dr. Yeu: I use an omega-3 fatty acid supplement to treat all forms of DED. Study data have shown improvements in DED signs and symptoms after just 30 to 45 days of use and improvement in dry eye after cataract surgery.¹²⁻¹⁴

SPONSORED SUPPLEMENT

Case Continued

The patient was instructed to use loteprednol etabonate gel, 0.5%, twice daily for 2 weeks, preservative-free artificial tears 4 times a day, to apply warm compresses to the eyelids, and to take an omega-3 fatty acid supplement. It was recommended that the omega-3 fatty acid supplement be taken in the triglyceride form at a dose of approximately 2000 mg/d.¹⁵

On return after 3 weeks, the patient was deemed ready for surgery. The topography was more regular and showed less dropout, and a keratoconus pattern was now clear (**Figure 2**).

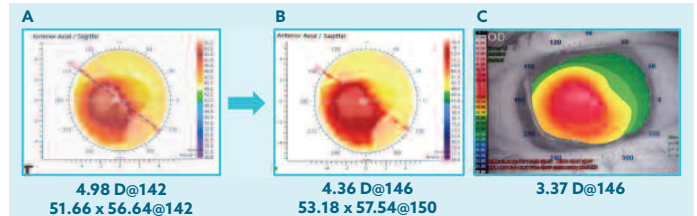


Figure 2. Findings from topography before (A) and after 3 weeks of treatment for dry eye (B and C). Following ocular surface optimization, a clear keratoconus pattern is visible on 2 separate topographies.

Images courtesy of Tal Raviv, MD

Dr. Raviv: What are the considerations for selecting an IOL in a patient with keratoconus?

Dr. Donnenfeld: First, contact lens status needs to be considered. A patient wearing a rigid gas permeable (RGP) contact lens who continues to wear the lens after surgery should not receive a toric IOL because the astigmatism of the implant, which is inside the eye, cannot be corrected with a contact lens.¹⁶ Assuming that the keratoconus is stable and the patient is not going to wear an RGP, I would consider a toric IOL to correct astigmatism if the astigmatism is regular and reproducible when measured with multiple modalities. I would avoid a multifocal or extended depth-of-focus IOL for any eye with an aberrated cornea.

Dr. Yeu: With steepening from the cone, eyes with keratoconus often have high negative corneal spherical aberration (SA),¹⁶ similar to eyes that are posthyperopic LASIK (laser in situ keratomileusis).¹⁷ You would not want to implant an aspheric IOL that adds negative SA.

Dr. Donnenfeld: A conventional spherical IOL that has positive SA would be optimal to compensate for the negative corneal SA if the IOL is centered under the cone. In this case and in most eyes with keratoconus, however, the cone is decentered from the pupil. Implanting an IOL with a positive or negative SA will create significant coma that will often make patients very unhappy with their vision. A zero SA lens is the better choice because it will do no harm in terms of inducing higher order aberrations. Only 1 of the toric IOLs available in the United States has zero SA; the others have negative SA (**Table 1**).¹⁸⁻²²

Table 1. Selected Specifications of Toric Intraocular Lens Options Available in the United States

Intraocular Lens	Optic Design	Spherical Aberration	Cylinder Power Range (Corneal Plane)
AcrySof IQ ¹⁸	Monofocal	Negative	1.03-4.11 D
AcrySof IQ ReSTOR ¹⁹	Multifocal	Negative	1.03-2.57 D
Trulign ²⁰	Accommodating	Zero	0.83-1.83 D
TECNIS ²¹	Monofocal	Negative	1.03-4.11 D
TECNIS Symphony ²²	Extended depth of focus	Negative	1.03-2.57 D

Dr Raviv: This patient was a good candidate for a toric IOL because he had never worn an RGP lens. Although he had high negative corneal SA, 0.785 μm , he also had fairly high astigmatism that could not be sufficiently corrected using the available zero SA toric IOL. Because I thought it was more important to treat the lower order aberration, the astigmatism, than the higher order aberration, the SA, I implanted an aspheric toric IOL with negative SA that corrects 4.11 D cylinder at the corneal plane.

Case Conclusion

Postoperatively, refraction was $-1.25 -0.50 \times 58$, BCVA was 20/20, and the patient went on to have the second eye procedure.

Dr Raviv: There are some additional considerations for getting good refractive results in eyes with keratoconus. For IOL power calculations, Watson and colleagues found predictability was improved by using the measured K value and a target of low myopia in eyes with K values ≤ 55 D and by using a standard K value of 43.25 D with a more myopic target for steeper eyes to avoid a hyperopic surprise.²³ Results of a study by Hashemi and colleagues favored using the topography-derived K value and SRK/T formula for eyes with mild or moderate keratoconus and the K value from topography and manual keratometry with the SRK/T or SRK II formulas for eyes with severe keratoconus.²⁴

I find that intraoperative aberrometry can be less reliable in eyes with keratoconus because even slight fixation movements with a central cone create large shifts in the intraoperative aberrometry readings. Increased risk for IOL rotation is also a concern, considering that keratoconic eyes tend to have longer axial lengths²⁵ and the risk for toric IOL rotation increases with increasing axial length.²⁶ To minimize the chance of IOL rotation, I check for 360° capsule overlap of the optic rim and leave the eye a little flat at the end of the procedure.

So long as there is no corneal scarring, there are no contraindications to performing femtosecond laser-assisted cataract surgery (FLACS) in an eye with keratoconus. We would not want to create corneal relaxing incisions because they could significantly worsen the already ectatic cornea.²⁷

Is there a role for corneal crosslinking before cataract surgery in a 70-year-old patient with keratoconus?

Dr Donnenfeld: Patients with keratoconus who have had good visual acuity for 20 years with glasses will probably have good vision after cataract surgery. But for patients who tell me they never saw well with glasses and were experiencing a lot of glare and halo, we now have the opportunity to address those complaints by performing topography-guided photorefractive keratectomy to regularize the central topography.²⁸ The laser ablation is done 3 months after corneal crosslinking; then, I would wait another 3 months before performing cataract surgery.

Some surgeons will perform simultaneous crosslinking and topographic ablation. In our experience, however, this can result in delayed healing, with corneal scarring and less predictable refractive outcomes.

CASE 2: A PATIENT WITH GLAUCOMA

From the Files of Robert J. Noecker, MD, MBA

A 63-year-old female presents with cataract OU. She has primary open-angle glaucoma OS, which was treated with selective laser trabeculoplasty in 2006. In 2004, she had conductive

keratoplasty OS and developed an IOP response to corticosteroid treatment.

The patient has DED and rosacea. Current medications are topical cyclosporine, 0.05%; travoprost, 0.004%; brimonidine, 0.1%; aspirin; and vitamins. Findings on examination are BCVA, 20/40-1 OD, 20/40-2 OS; refraction, $+1.00 -1.00 \times 90$ OU; pachymetry, 544 μm OD, 538 μm OS; IOP, 19 mm Hg OD, 20 mm Hg OS; and 2 to 3+ NS cataract OD and 2+ NS cataract with 1+ anterior cortical changes OS.

She has a normal disc OD, with a cup/disc ratio of 0.5×0.4 , and an inferotemporal retinal nerve fiber layer (RNFL) wedge defect OS, with a cup/disc ratio of 0.8×0.7 . The macula and retinal vessels and periphery are normal OU. Visual field testing shows progression OD, with paracentral defects, and no progression OS. Optical coherence tomography (OCT) findings were consistent, with some thinning of the RNFL OD and no definite progression OS.

Dr Noecker: This patient has moderate glaucoma that has been fairly well controlled, but her need for cataract surgery offers a new opportunity for intervention. After cataract surgery, there is better visualization of the posterior segment and IOP is often reduced.²⁹

In addition, we now have options for performing a concomitant minimally invasive glaucoma surgery (MIGS) procedure to control IOP and to reduce medication use and its associated drawbacks, one being poor compliance. According to various studies, up to 80% of patients are noncompliant with their glaucoma medications and 50% stop using their medications by 6 months.^{30,31} Compliance also worsens with increasing complexity of the treatment regimen.³²

The potential for causing ocular surface disease (OSD) is another concern accompanying use of topical medications for glaucoma. Pisella and colleagues found that nearly 60% of patients with medically treated glaucoma reported OSD symptoms and that the prevalence of OSD signs and symptoms increased with the increasing number of preservative-containing drops.³³

Dr Yeu: Prostaglandin analogues (PGAs) are strongly associated with meibomian gland dysfunction (MGD), and this association may be seen in > 90% of PGA users.^{34,35}

Dr Noecker: There are potential benefits for performing combined cataract and glaucoma surgery. Although the MIGS procedures have a better safety profile than trabeculectomy and are relatively atraumatic, they add manipulation, which can increase bleeding and inflammation. Although the differences between patients undergoing combination supraciliary microstent/ataract surgery and those undergoing cataract surgery alone were not statistically significant in the COMPASS trial, the combined surgery group had a higher rate of iritis than the group having cataract surgery alone (8.6% vs 3.8%), and the combined surgery group also had more subconjunctival hemorrhage (1.6% vs 0.8%) and cystoid macular edema (CME) (1.3% vs 0.8%) than the group having cataract surgery alone.³⁶

Corticosteroids and/or nonsteroidal anti-inflammatory drugs (NSAIDs) are used to control inflammation after cataract surgery, but the patient in this case was a steroid responder.

Would you use an NSAID alone?

Dr Raviv: I rarely use an NSAID alone to control inflammation after cataract surgery because NSAIDs act synergistically with corticosteroids for preventing the development of CME.³⁷ With

FOR INSTANT PROCESSING, COMPLETE THE CME POST TEST ONLINE
[HTTPS://TINYURL.COM/CATARACTANDREFRACTIVECASES](https://tinyurl.com/cataractandrefractivecases)

the results from the randomized controlled Prevention of Macular Edema After Cataract Surgery (PREMED) study, we have even more evidence to supporting a benefit for using the combination to reduce the development of CME.³⁸

Among the topical corticosteroids, loteprednol and fluorometholone have a reduced tendency to increase IOP,^{10,39} and loteprednol, 0.5%, has been shown to be equivalent to prednisolone acetate, 1%, for controlling inflammation after routine cataract surgery.⁴⁰

If I am concerned about an IOP response, I prescribe loteprednol, 0.5%. I like the gel formulation because it is “friendly” to the ocular surface. The gel has a pH of 6.5, a low concentration of benzalkonium chloride, and ingredients that are ocular lubricants.³⁹

Dr Yeu: The gel formulation of loteprednol, 0.5%, also has increased contact time, which should improve its bioavailability.³⁹ I think this attribute contributes to its efficacy, and in my hands, I find that loteprednol gel is more reliably effective than prednisolone acetate, which is usually dispensed as a generic product.

Dr Donnenfeld: There is much controversy about the benefit of NSAIDs in cataract surgery. A 2015 report from the American Academy of Ophthalmology concluded there is a lack of level I evidence that NSAIDs prevent vision loss from CME at ≥ 3 months.⁴¹ In contrast, European investigators conducting a systematic review and meta-analysis concluded that topical NSAIDs alone, or combined with a corticosteroid, significantly reduced the risk of CME compared with topical corticosteroid treatment alone in both diabetic and nondiabetic patients.⁴²

We now have level I evidence from the PREMED study to show benefit of NSAIDs in reducing the risk of CME.³⁸ Sponsored by the European Society of Cataract & Refractive Surgeons, PREMED included 914 nondiabetic patients having routine cataract surgery who were randomized to receive bromfenac, 0.09%, dexamethasone, 0.1%, or bromfenac plus dexamethasone. The incidence of clinically significant macular edema (defined as CME with < 0.2 logMAR corrected distance visual acuity improvement vs baseline) in the NSAID, steroid, and combined groups was 3.6%, 5.1%, and 1.5%, respectively.

On the basis of the findings from this rigorously designed study, I believe an NSAID should be used routinely in all patients. PREMED also included a cohort of 213 patients with diabetes and found benefits for adding subconjunctival triamcinolone acetonide 40 mg to bromfenac and dexamethasone compared with use of just bromfenac plus dexamethasone.³⁸

Dr Yeu: In patients with diabetes who are not IOP responders, I give a sub-Tenon injection of triamcinolone acetonide 2 mg.

Dr Noecker: Dr Donnenfeld, do you have a preference for brand name vs generic NSAIDs?

Dr Donnenfeld: I do. I think ketorolac is a very effective NSAID, but it is available now only as generic ketorolac, 0.5%, which causes a lot of burning and discomfort. In fact, the incidence of stinging and burning on instillation of ketorolac, 0.5%, was up to 40% in US Food and Drug Administration trials.

Dr Raviv: If patients tell me they want to fill their antibiotic, corticosteroid, and NSAID prescriptions with generic drugs because of cost, I urge them not to allow the pharmacist to substitute the brand name NSAID. Compared with generic

ketorolac, the brand name NSAIDs I prescribe have once-daily dosing and are more comfortable upon instillation.

Dr Yeu: I think patients do best with medications that are used just once daily, and this regimen is recommended for only 2 brand name NSAIDs: nepafenac, 0.3%, and bromfenac, 0.07%.^{43,44}

Case Conclusion

The patient underwent uneventful FLACS with MIGS using a supraciliary microstent. She was treated for 1 month with loteprednol etabonate gel, 0.5%, twice daily and nepafenac, 0.3%, once daily. Postoperatively, her IOP off medication was 15 mm Hg. She was restarted on travoprost alone. Her OSD improved and her uncorrected visual acuity was 20/25 at 1 month.

CASE 3: A PATIENT WITH A CORNEAL TRANSPLANT

From the Files of Eric D. Donnenfeld, MD

A 54-year-old male presents with visually significant cataract. He has a history of herpes simplex virus (HSV) keratitis OD and underwent penetrating keratoplasty (PK) in 2006, followed by 2 graft injections and 2 herpetic infection recurrences. Current treatment includes loteprednol gel, 0.5%, 1 drop daily for the past 6 months and oral valacyclovir 500 mg daily, which he has been on for 5 years.

Dr Donnenfeld: With a history of 2 herpetic infection recurrences, this patient needs to be kept on antiviral prophylaxis, and oral valacyclovir is generally well tolerated long term. I also prescribe oral valacyclovir for acute HSV epithelial keratitis.

Dr Yeu, do you use topical antiviral therapy for HSV epithelial keratitis?

Dr Yeu: Trifluridine, 1%, was the only US Food and Drug Administration–approved topical option for some time, but it is associated with significant epithelial toxicity.^{45,46} For that reason, I would use oral acyclovir or valacyclovir. We now have ganciclovir gel, 0.15%, which I particularly like for patients who cannot take oral medications. Little is published about the use of topical ganciclovir to prevent HSV keratitis recurrence.⁴⁷ Although I am not aware of any published reports of topical ganciclovir to prevent virus reactivation in a patient with a history of herpetic infection who is undergoing surgery, I do prescribe it on the same frequency schedule as that of a topical corticosteroid.

Case Continued

Diagnostic imaging is ordered, including OCT of the macula and optic nerve, specular microscopy (Figure 3), and corneal topography (Figure 4).




Figure 3. Specular microscopy OD (A) and OS (B). Note endothelial cell count of 1523 cells/mm² and very large polygonal cells OD
Image courtesy of Eric D. Donnenfeld, MD

SPONSORED SUPPLEMENT

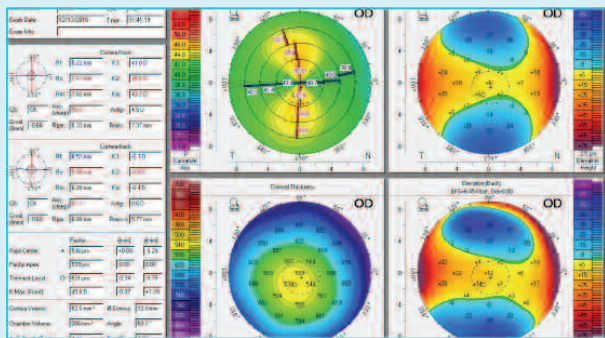


Figure 4. Corneal topography shows 4.5 D of regular with-the-rule astigmatism

Image courtesy of Eric D. Donnenfeld, MD

Dr Donnenfeld: All these tests are important, but I am particularly interested in seeing the specular microscopy in an eye with a corneal transplant. The low endothelial cell count and morphology tell me this patient may need another transplant in the future. He needs to be informed about this preoperatively. If you tell a patient about something before surgery, it becomes an expectation, but if you wait until after surgery, it becomes a complication. I also know that when performing the cataract surgery, I need to pay special attention to endothelial protection and inflammation control.

Dr Raviv: The topography is important because a post-PK patient will have astigmatism, which may be treated during cataract surgery.

Dr Donnenfeld: For years, I have seen patients who struggled with visual rehabilitation after a corneal transplant. They have anisometropia and have to wear contact lenses, often hard contact lenses, and I wonder why they did not have cataract surgery earlier. One of the most rewarding procedures that I do on a routine basis is cataract surgery in postcorneal transplant patients because it can address their visual disability.

Dr Yeu: I agree. Just as in the patient with keratoconus, we have to discern what part of the blurred vision is coming from the cornea itself vs from the cataract. If the BCVA achieved is the same between the phoropter refraction and the RGP overrefraction, then the cataract is causing the decreased vision. But if the BCVA achieved via the RGP overrefraction is better than the BCVA from the phoropter, the irregular cornea is responsible for the difference seen. Cataract surgery is a huge opportunity for improving quality of vision because whenever a patient has more than 2 D of astigmatism, there is much better quality of vision if it is corrected at the IOL plane rather than at the spectacle plane.

Dr Donnenfeld: Dr Noecker, do you get a macula OCT on most of your patients undergoing cataract surgery?

Dr Noecker: I get a macula OCT on all my patients, but I think it is especially important for a patient with glaucoma who had a prior procedure and is undergoing cataract surgery because I think this type of patient is at a higher risk for developing CME. If I consider starting a PGA postoperatively, I want to know if there is any preexisting macular problem that might predispose to CME after the cataract surgery. I also get an RNFL scan routinely because it can pick up subtleties that are missed on the optic nerve examination. Significant RNFL loss may affect our choice of IOL and the decision to perform a combination procedure.

Dr Donnenfeld: Dr Raviv, what pearls do you have about protecting the endothelium during cataract surgery?

Dr Raviv: I would use a dispersive viscoelastic that will coat and protect the endothelium, and I would consider reapplying it during the procedure. There is evidence that a scleral incision may be associated with less endothelial cell loss than a corneal incision.⁴⁸ I would be sure to work inside the capsular bag and might consider using a femtosecond laser to pretreat the lens because it can reduce ultrasound energy use.^{49,50}

Dr Donnenfeld: FLACS has other potential benefits, including improved capsulotomy precision, which can translate into improved refractive predictability.⁴⁹⁻⁵¹ In addition, the laser can be used to place an intrastromal incision as a reference mark for toric IOL.

This patient had high astigmatism and approximately 4 D of anisometropia. If I were to perform a limbal relaxing incision (LRI), I would place it within the graft, but I think correction of astigmatism in a post-PK patient is really best done with a toric IOL.

I have seen IOL rotation in a number of post-PK eyes, and I believe it occurred because secondary to the size disparity between the graft and the recipient bed, post-PK eyes have a relatively large anterior chamber. With this issue in mind, which toric IOL would you choose?

Dr Yeu: An analysis including data for 4 toric IOL models showed the toric version of the accommodative IOL had the lowest rate of misorientation $\geq 5^\circ$ from the intended axis.⁵² I believe the rotational stability of this particular toric IOL is enhanced by its 4-point open-loop haptic design.

Dr Donnenfeld: Is there anything else you would consider using to achieve the desired refractive outcome in this case?

Dr Raviv: I would use intraoperative aberrometry.

Dr Donnenfeld: I think that makes sense, and some digital marking systems are also helpful for achieving precise alignment, which is crucial for getting a good refractive and visual outcome. For every 3° that a toric IOL is off axis, it loses approximately 10% of its correction effect.⁵³

Cataract surgery increases the risk for immune graft rejection.⁵⁴ How would you control inflammation in this patient who is a steroid responder?

Dr Yeu: It is important to have a discussion with patients after their transplants about the importance of adhering to their prescribed medication regimens. I explain that after cataract surgery, they will need to be on a corticosteroid with a prolonged taper to protect the graft, just as they were after the transplant, and I follow IOP closely.

Dr Donnenfeld: I planned to keep this patient on a once-daily steroid indefinitely. If you are beginning with 4-times-a-day administration, how long would it be before you tapered this patient to once-daily dosing?

Dr Yeu: I would do the taper over 3 to 4 months.

Dr Donnenfeld: I agree with that approach, whereas in a routine case, the patient would reach the once-daily dose after 3 weeks. I also kept this patient on an NSAID for 1 month.

Dr Noecker, how would you manage an IOP elevation?

FOR INSTANT PROCESSING, COMPLETE THE CME POST TEST ONLINE
[HTTPS://TINYURL.COM/CATARACTANDREFRACTIVECASES](https://tinyurl.com/cataractandrefractivecases)

Dr Noecker: Controlling the IOP is also important because glaucoma is a risk factor for graft failure.⁵⁵ I would choose a medication that is used just once daily because this enables adherence and minimizes preservative exposure. The once-daily options include all the PGAs and 2 new once-daily options with novel mechanisms of action: latanoprostene bunod and netarsudil. Among the PGAs, latanoprost, bimatoprost, and travoprost are all available as generic drugs. Compared with the generic version, the branded bimatoprost product contains a lower concentration of active ingredient and is associated with fewer side effects.⁵⁶ The branded version of travoprost is formulated with a non-benzalkonium chloride preservative, and brand name tafluprost is preservative free.

Dr Donnenfeld: Postoperatively, I also increased the antiviral therapy in this patient to valacyclovir 500 mg twice daily for 1 month before returning to the once-daily regimen and used a fourth-generation fluoroquinolone for 10 days, which I do routinely. Besifloxacin has become my antibiotic of choice because it has a broad spectrum and is more potent than other fluoroquinolones against the Gram-positive pathogens that are the most common causes of endophthalmitis.⁵⁷

Case Conclusion

Cornea clarity was maintained after surgery. Astigmatism was reduced to < 1 D, and the patient was very happy with the outcome.

CASE 4: A COMPLEX MEDICAL HISTORY LEADING TO SEVERE DRY EYE DISEASE

From the Files of Elizabeth Yeu, MD

A 71-year-old female presents for evaluation of blurred vision and cataract. She is a physician's wife and former nurse and states that she is not ready for cataract surgery. She has been treated for DED by her referring ophthalmologist and tried cyclosporine ophthalmic emulsion, 0.05%, and lifitegrast, 5%, but discontinued each within 1 to 2 weeks because of ocular discomfort. She states that she uses preservative-free artificial tear gels and ointments every 30 to 60 minutes.

The patient had lagophthalmos associated with Guillain-Barré syndrome in the distant past. She was unable to completely close her eyelids, and although the suspected cause was previous blepharoplasties, she denied having any eyelid surgery. Current medications are clonidine, rosuvastatin, furosemide, and duloxetine, along with several medications for pain, including fentanyl patch, hydromorphone, and butalbital/acetaminophen/caffeine.

Her Standard Patient Evaluation of Eye Dryness (SPEED) score is 6; osmolarity is 327/331 mOsm/L OD/OS; tear break-up time is 1 to 2 seconds OU; and she has 2+ MGD with telangiectasis OU. She has a poor blink rate, with lag OD > OS (1 to 2 mm), diffuse 2 to 3+ stain within the central and inferior cornea OD, and corneal neovascularization with anterior stromal scar in the inferior periphery.

Meibography shows serpiginous, congested meibomian glands, with 25% to 33% dropout and mild truncation (**Figure 5**). **Figure 6** shows the topography images.

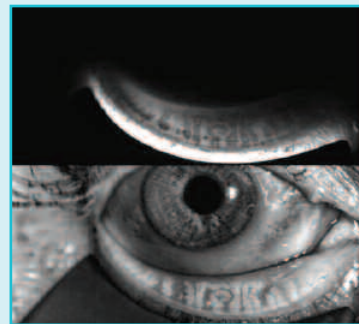


Figure 5. Meibography shows mild-to-moderate architectural damage of the meibomian glands, as seen by the tortuosity, congestion of the existing glands, and dropout of other glands

Image courtesy of Elizabeth Yeu, MD

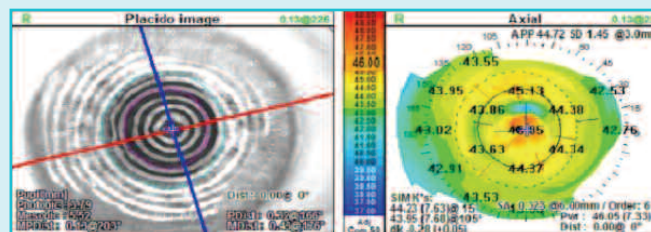


Figure 6. The Placido image demonstrates the smudgy, irregular mires that are seen throughout which correlates with the irregular topography on the axial map. The irregular and poor quality of the mires are due to the diffuse epitheliopathy from the chronic dry eye disease and exposure keratopathy, leading to central staining of the cornea

Images courtesy of Elizabeth Yeu, MD

Dr Yeu: This patient's SPEED score is surprisingly low, and I think that speaks to a neurotrophic component to her DED. She has a chronic, diffuse exposure keratopathy that makes it challenging to provide adequate ocular surface protection, even with frequent use of artificial tears. The mires on topography are irregular and have a smudgy appearance which correlates very well with the central island of steepening. I expected her MGD to be more severe than it was, so I believe MGD is not the primary cause for her DED. Rather, I think this case illustrates how one of the DED subtypes, evaporative or aqueous deficient, can lead to the other.

How would you approach management for this patient who has such severe, multifactorial DED?

Dr Raviv: It will be important to address the exposure keratopathy, which can be done with oculoplastic surgery or perhaps by using punctal plugs or a slow-release ocular lubricant insert.

Dr Donnenfeld: I agree that she will need lid surgery for the exposure and perhaps a small tarsorrhaphy. I think she is also a good candidate for an in-office lid warming/thermal pulsation procedure to relieve meibomian gland obstruction, and I would recommend omega-3 fatty acid supplementation, topical corticosteroid treatment, and autologous serum tears, which I think are underused in such advanced cases.

Dr Yeu: This patient needs aggressive intervention because of the severity of her condition. Topical corticosteroid treatment can be extremely helpful for acute management of DED.⁸⁹ In this case, however, it may not be sufficient. Placement of a self-retaining

SPONSORED SUPPLEMENT

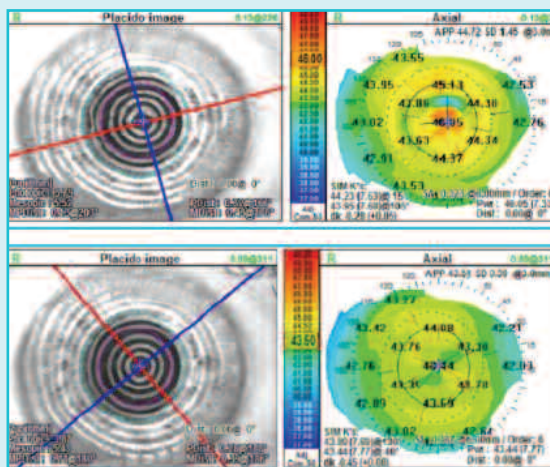


Figure 7. Images from Placido disk topography prior to treatment (top) show diffuse irregularity of the mires, coinciding with irregular astigmatism on the axial map. Improvement is seen in images taken 1 week after placement of a self-retaining cryopreserved amniotic membrane (bottom). Images courtesy of Elizabeth Yeu, MD

cryopreserved amniotic membrane may be a good option because such a procedure has been reported to rapidly restore ocular integrity in eyes with moderate-to-severe DED.⁵⁸

Case Continued

A self-retaining cryopreserved amniotic membrane was placed OD and the upper lid was closed for 5 days with a tape tarsorrhaphy. When the patient returned the next day, her topography showed marked improvement (**Figure 7**).

Dr Yeu: Although it was possible to rapidly normalize the corneal epithelium using the cryopreserved amniotic membrane, it is unlikely that this condition can be maintained long term. Therefore, I would not consider a multifocal IOL for this patient. Instead, I would choose a single focus lens, either a monofocal IOL or an accommodating IOL.

The patient must still understand that cataract surgery can worsen DED and that continued treatment for existing DED will be needed for optimal quality of vision long term. There are many different options for ongoing DED management. Dr Donnenfeld recently reported a study showing that placement of temporary punctal plugs after LASIK improved ocular surface quality and quality of vision.⁵⁹ I expect we would see the same benefits using punctal plugs after cataract surgery, especially in a patient such as the one in this case.

Would you perform FLACS in an eye that has more severe DED?

Dr Raviv: I typically do not defer FLACS because of mild-to-moderate dry eye. I treat the dry eye first. In an extreme recalcitrant DED case, however, I might select a manual procedure to avoid suction ring placement.

"I typically do not defer FLACS because of mild-to-moderate dry eye. I treat the dry eye first."

—Tal Raviv, MD

Dr Donnenfeld: If a patient required astigmatism correction, I would not perform penetrating LRIs with the laser or manually because the procedure might exacerbate DED. We found significant loss of corneal sensation and increased corneal staining adjacent to these astigmatic-correcting incisions.

Dr Yeu: The patient was ready for cataract surgery, but I paid special attention to endophthalmitis prophylaxis.

Most cases of postcataract surgery endophthalmitis are caused by a Gram-positive organism.^{57,60} Coagulase-negative staphylococci followed by *Staphylococcus aureus* are the leading pathogens, and a recent analysis from the ARMOR (Antibiotic Resistance Monitoring in Ocular Microorganisms) surveillance study of presumed endophthalmitis isolates showed that approximately one-half of the coagulase-negative staphylococci strains and one-third of the *S aureus* strains were methicillin resistant.

Table 2 lists the minimum inhibitory concentration that inhibits the growth of 90% of indicated isolates (MIC₉₀) for presumed endophthalmitis isolates collected in the ARMOR surveillance study.⁵⁷ Clinicians might also consider local susceptibility data.

"Coagulase-negative staphylococci followed by Staphylococcus aureus are the leading pathogens (for endophthalmitis), and a recent analysis from the ARMOR Surveillance Study of presumed endophthalmitis isolates showed that approximately one-half of the coagulase-negative staphylococci strains and one-third of the S aureus strains were methicillin resistant."

—Elizabeth Yeu, MD

Table 2. ARMOR Surveillance Study MIC₉₀ Values for Presumed Endophthalmitis Isolates⁵⁷

Antibiotic	MIC ₉₀ (µg/mL)			
	MSSA	MRSA	MSCoNS	MRCoNS
Vancomycin	1	1	2	2
Besifloxacin	0.03	2	1	4
Gatifloxacin	0.12	32	16	64
Moxifloxacin	0.06	32	16	64
Ciprofloxacin	0.5	256	64	64
Tobramycin	0.5	> 256	8	4
Azithromycin	> 512	> 512	> 512	> 512

Abbreviations: MIC₉₀, minimum inhibitory concentration that inhibits the growth of 90% of indicated isolates; MRCoNS, methicillin-resistant coagulase-negative staphylococci; MRSA, methicillin-resistant *Staphylococcus aureus*; MSCoNS, methicillin-susceptible coagulase-negative staphylococci; MSSA, methicillin-susceptible *Staphylococcus aureus*.

I think that the evidence supporting intracameral antibiotic prophylaxis for endophthalmitis is overwhelming.^{61,62} Is anyone using intracameral antibiotics for postcataract surgery endophthalmitis prophylaxis?

Dr Noecker: We use intracameral antibiotics routinely. We inject vancomycin for the first eye, but a different antibiotic for the second eye, usually a cephalosporin, because of concern for hemorrhagic occlusive retinal vasculitis (HORV) with intraocular vancomycin.⁶³

FOR INSTANT PROCESSING, COMPLETE THE CME POST TEST ONLINE
[HTTPS://TINYURL.COM/CATARACTANDREFRACTIVECASES](https://tinyurl.com/cataractandrefractivecases)

Dr Yeu: HORV is a rare but potentially devastating complication that has been associated with vancomycin.⁶³ Findings of a retrospective review including 36 affected eyes of 23 patients showed that in patients with bilateral HORV, the course was more severe in the second eye.⁶³ Most eyes in the series had received an intracameral injection of vancomycin; apart from that, the agent was given via intravitreal injection in 1 eye and administered intracamerally through the irrigation bottle in 2 eyes. Visual acuity was 20/200 or worse in 61% of eyes, and 22% had no light perception vision. Vision loss was usually delayed in onset. Mean time to occurrence was 8 days in this series and ranged up to 21 days. The most common complication was neovascular glaucoma, which occurred in 56% of eyes.

Dr Donnenfeld: We began using intracameral antibiotics approximately 10 years ago, and anecdotally have found that they reduced the incidence of endophthalmitis at our surgical center approximately 4-fold. Because of the risk for HORV with intracameral vancomycin,⁶³ we have switched to using moxifloxacin.

Dr Yeu: Given the published documentation of HORV,⁶³ it makes sense from a medicolegal perspective to avoid intracameral vancomycin.

Case Conclusion

The patient was started on topical treatment with besifloxacin, 0.06% twice daily; difluprednate, 0.05%, twice daily; and bromfenac, 0.07%, once daily 1 day prior to surgery for each eye. She underwent FLACS with small intrastromal LRIs to correct her astigmatism and implantation of a monofocal IOL OU. Postoperative uncorrected distance visual acuity was 20/25 OU.

The patient was started on a tapering course of a topical corticosteroid. Once the ocular surface inflammation was controlled, she was able to tolerate reinstatement of topical lifitegrast, and inferior punctal occlusion was planned. She was also started on an omega-3 fatty acid supplement for long-term DED management.

SPONSORED SUPPLEMENT

TAKE-HOME POINTS FOR CATARACT SURGERY...

In eyes with keratoconus

- Avoid relaxing incisions
- Use a toric IOL if an RGP contact lens will not be worn postoperatively and if multiple sources provide reproducible K readings
- Consider corneal SA when selecting an IOL; consider the severity of steepening when calculating power

In eyes with glaucoma

- Beware that chronic use of glaucoma medications is associated with OSD
- Consider concomitant MIGS in appropriate patients to control IOP and reduce glaucoma medication burdens
- Recognize that postoperative inflammation tends to be higher after combined surgery

In eyes with prior PK

- Use strategies to protect the cornea and graft
- FLACS may have advantages
- Toric IOLs may be used to reduce astigmatism

In all eyes

- Recognize and manage DED preoperatively and postoperatively
- Evidence supports intracameral antibiotic use for endophthalmitis prophylaxis, but consider the risk of HORV and infections caused by methicillin-resistant staphylococci when selecting an agent
- Use an NSAID with a corticosteroid to control inflammation

REFERENCES

1. Trattler WB, Majmudar PA, Donnenfeld ED, McDonald MB, Stonecipher KG, Goldberg DF. The Prospective Health Assessment of Cataract Patients' Ocular Surface (PHACO) study: the effect of dry eye. *Clin Ophthalmol*. 2017;11:1423-1430.
2. Montés-Micó R. Role of the tear film in the optical quality of the human eye. *J Cataract Refract Surg*. 2007;33(9):1631-1635.
3. Epitropoulos AT, Matossian C, Berdy GJ, Malhotra RP, Potvin R. Effect of tear osmolarity on repeatability of keratometry for cataract surgery planning. *J Cataract Refract Surg*. 2015;41(8):1672-1677.
4. Goto E, Yagi Y, Matsumoto Y, Tsubota K. Impaired functional visual acuity of dry eye patients. *Am J Ophthalmol*. 2002;133(2):181-186.
5. Tutt R, Bradley A, Begley C, Thibos LN. Optical and visual impact of tear break-up in human eyes. *Invest Ophthalmol Vis Sci*. 2000;41(13):4117-4123.
6. Behrens A, Doyle JJ, Stern L, et al. Dysfunctional tear syndrome: a Delphi approach to treatment recommendations. *Cornea*. 2006;25(8):900-907.
7. Woodward MA, Randleman JB, Stulting RD. Dissatisfaction after multifocal intraocular lens implantation. *J Cataract Refract Surg*. 2009;35(6):992-997.
8. Pflugfelder SC, Maskin SL, Anderson B, et al. A randomized, double-masked, placebo-controlled, multicenter comparison of loteprednol etabonate ophthalmic suspension, 0.5%, and placebo for treatment of keratoconjunctivitis sicca in patients with delayed tear clearance. *Am J Ophthalmol*. 2004;138(3):444-457.
9. Foulks GN, Forstot SL, Donshik PC, et al. Clinical guidelines for management of dry eye associated with Sjögren disease. *Ocul Surf*. 2015;13(2):118-132.
10. Comstock TL, Decory HH. Advances in corticosteroid therapy for ocular inflammation: loteprednol etabonate. *Int J Inflam*. 2012;2012:789623.
11. Samudre SS, Lattanzio FA Jr, Williams PB, Sheppard JD Jr. Comparison of topical steroids for acute anterior uveitis. *J Ocul Pharmacol Ther*. 2004;20(6):533-547.
12. Bhargava R, Kumar P, Arora Y. Short-term omega 3 fatty acids treatment for dry eye in young and middle-aged visual display terminal users. *Eye Contact Lens*. 2016;42(4):231-236.
13. Kangari H, Eftekhari MH, Sardari S, et al. Short-term consumption of oral omega-3 and dry eye syndrome. *Ophthalmology*. 2013;120(11):2191-2196.
14. Mohammadpour M, Mehrabi S, Hassanpoor N, Mirhashi R. Effects of adjuvant omega-3 fatty acid supplementation on dry eye syndrome following cataract surgery: a randomized clinical trial. *J Curr Ophthalmol*. 2016;29(1):33-38.
15. Epitropoulos AT, Donnenfeld ED, Shah ZA, et al. Effect of oral re-esterified omega-3 nutritional supplementation on dry eyes. *Cornea*. 2016;35(9):1185-1191.
16. Moshirfar M, Walker BD, Birdsong OC. Cataract surgery in eyes with keratoconus: a review of the current literature. *Curr Opin Ophthalmol*. 2018;29(1):75-80.
17. Llorente L, Barbero S, Merayo J, Marcos S. Total and corneal optical aberrations induced by laser in situ keratomileusis for hyperopia. *J Refract Surg*. 2004;20(3):203-216.
18. ACRYSof IQ Toric Astigmatism IOL [package insert]. Fort Worth, TX: Alcon Laboratories, Inc; 2011.
19. ACRYSof IQ ReSTOR Multifocal Toric IOL [package insert]. Fort Worth, TX: Alcon Laboratories, Inc; 2016.
20. Trulign Toric [package insert]. Aliso Viejo, CA: Bausch & Lomb Incorporated; 2013.
21. TECNIS Toric 1-Piece [package insert]. Santa Ana, CA: Abbott Medical Optics Inc; 2015.
22. TECNIS Symphony Extended Range of Vision IOL [package insert]. Santa Ana, CA: Abbott Medical Optics Inc; 2016.
23. Watson MP, Anand S, Bhogal M, et al. Cataract surgery outcome in eyes with keratoconus. *Br J Ophthalmol*. 2014;98(3):361-364.
24. Hashemi H, Heidarian S, Seyedian MA, Yekta A, Khabazkhoob M. Evaluation of the results of using toric IOL in the cataract surgery of keratoconus patients. *Eye Contact Lens*. 2015;41(6):354-358.
25. Ernst BJ, Hsu HY. Keratoconus association with axial myopia: a prospective biometric study. *Eye Contact Lens*. 2011;37(1):2-5.
26. Zhu X, He W, Zhang K, Lu Y. Factors influencing 1-year rotational stability of AcrySof toric intraocular lenses. *Br J Ophthalmol*. 2016;100(2):263-268.
27. Wellish KL, Glasgow BJ, Beltran F, Maloney RK. Corneal ectasia as a complication of repeated keratotomy surgery. *J Refract Corneal Surg*. 1994;10(3):360-364.
28. Kontadakis GA, Kankariya VP, Tsoularas K, Pallikaris AI, Plaka A, Kymionis GD. Long-term comparison of simultaneous topography-guided photorefractive keratectomy followed by corneal cross-linking versus corneal cross-linking alone. *Ophthalmology*. 2016;123(5):974-983.
29. Brown RH, Zhong L, Lynch MG. Lens-based glaucoma surgery: using cataract surgery to reduce intraocular pressure. *J Cataract Refract Surg*. 2014;40(8):1255-1262.
30. Olthoff CM, Schouten JS, van de Borne BW, Webers CA. Noncompliance with ocular hypotensive treatment in patients with glaucoma or ocular hypertension: an evidence-based review. *Ophthalmology*. 2005;112(6):953-961.
31. Nordstrom BL, Friedman DS, Mozaffari E, Quigley HA, Walker AM. Persistence and adherence with topical glaucoma therapy. *Am J Ophthalmol*. 2005;140(4):598-606.
32. Robin AL, Covert D. Does adjunctive glaucoma therapy affect adherence to the initial primary therapy? *Ophthalmology*. 2005;112(5):863-868.
33. Pisella PJ, Pouliquen P, Baudouin C. Prevalence of ocular symptoms and signs with preserved and preservative free glaucoma medication. *Br J Ophthalmol*. 2002;86(4):418-423.
34. Mocan MC, Uzunosmanoglu E, Kocabeyoglu S, Karakaya J, Irkek M. The association of chronic topical prostaglandin analog use with meibomian gland dysfunction. *J Glaucoma*. 2016;25(9):770-774.
35. Cunniffe MG, Medel-Jiménez R, González-Candial M. Topical antiglaucoma treatment with prostaglandin analogues may precipitate meibomian gland disease. *Ophthalm Plast Reconstr Surg*. 2011;27(5):e128-e129.
36. Vold S, Ahmed II, Craven ER, et al. Two-year COMPASS Trial results: supraciliary microstenting with phacoemulsification in patients with open-angle glaucoma and cataracts. *Ophthalmology*. 2016;123(10):2103-2112.
37. Hoffman RS, Braga-Mele R, Donaldson K, et al. Cataract surgery and nonsteroidal antiinflammatory drugs. *J Cataract Refract Surg*. 2016;42(9):1368-1379.
38. Harrison L. Steroid and NSAID combination prevents macular oedema after cataracts. *Ophthalmol Times*. <http://ophthalmologytimes.modernmedicine.com/ophthalmologytimes/news/steroid-and-nsaid-combination-prevents-macular-oedema-after-cataracts>. Published November 2, 2017. Accessed February 22, 2018.
39. Coffey MJ, Decory HH, Lane SS. Development of a non-settling gel formulation of 0.5% loteprednol etabonate for anti-inflammatory use as an ophthalmic drop. *Clin Ophthalmol*. 2013;7:299-312.
40. Lane SS, Holland EJ. Loteprednol etabonate 0.5% versus prednisolone acetate 1.0% for the treatment of inflammation after cataract surgery. *J Cataract Refract Surg*. 2013;39(2):168-173.
41. Kim SJ, Schoenberger SD, Thorne JE, Ehlers JP, Yeh S, Bakri SJ. Topical nonsteroidal anti-inflammatory drugs and cataract surgery: a report by the American Academy of Ophthalmology. *Ophthalmology*. 2015;122(11):2159-2168.
42. Wielders LH, Lambermont VA, Schouten JS, et al. Prevention of cystoid macular edema after cataract surgery in nondiabetic and diabetic patients: a systematic review and meta-analysis. *Am J Ophthalmol*. 2015;160(5):968-981.e33.
43. ILEVRO [package insert]. Fort Worth, TX: Alcon Laboratories, Inc; 2017.
44. PROLENSA [package insert]. Tampa, FL: Bausch & Lomb Incorporated; 2013.
45. VIROPTIC Ophthalmic Solution, 1% Sterile [package insert]. New York, NY: Pfizer Inc; 2016.
46. White ML, Chodosh J. *Herpes Simplex Virus Keratitis: A Treatment Guideline*. Boston, MA; 2014.
47. Wang X, Wang L, Wu N, Ma X, Xu J. Clinical efficacy of oral ganciclovir for prophylaxis and treatment of recurrent herpes simplex keratitis. *Chin Med J*. 2015;128(1):46-50.
48. Beltrame G, Salvatet ML, Driussi G, Chizzolini M. Effect of incision size and site on corneal endothelial changes in cataract surgery. *J Cataract Refract Surg*. 2002;28(1):118-125.
49. Popovic M, Campos-Möller X, Schlenker B, Ahmed II. Efficacy and safety of femtosecond laser-assisted cataract surgery compared with manual cataract surgery: a meta-analysis of 14 567 eyes. *Ophthalmology*. 2016;123(10):2113-2126.
50. Chen X, Xiao W, Ye S, Chen W, Liu Y. Efficacy and safety of femtosecond laser-assisted cataract surgery versus conventional phacoemulsification for cataract: a meta-analysis of randomized controlled trials. *Sci Rep*. 2015;5:13123.
51. Ye Z, Li Z, He S. A meta-analysis comparing postoperative complications and outcomes of femtosecond laser-assisted cataract surgery versus conventional phacoemulsification for cataract. *J Ophthalmol*. 2017;2017:3849152.
52. Potvin R, Kramer BA, Hardten DR, Berdahl JP. Toric intraocular lens orientation and residual refractive astigmatism: an analysis. *Clin Ophthalmol*. 2016;10:1829-1836.
53. Bauer NJ, de Vries NE, Webers CA, Hendrikse F, Nuijts RM. Astigmatism management in cataract surgery with the AcrySof toric intraocular lens. *J Cataract Refract Surg*. 2008;34(9):1483-1488.
54. Nagra PK, Rapuano CJ, Laibson PL, Kunimoto DY, Kay M, Cohen EJ. Cataract extraction following penetrating keratoplasty. *Cornea*. 2004;23(4):377-379.
55. Yu AL, Kaiser M, Schaumberger M, Messmer E, Kook D, Welge-Lüssen U. Perioperative and postoperative risk factors for corneal graft failure. *Clin Ophthalmol*. 2014;8:1641-1647.
56. Chambers WA. *Summary Review. Application Number: 22-184*. Silver Spring, MD: Center for Drug Evaluation and Research; 2010.
57. Asbell PA, Mah FS, Sanfilippo CM, DeCory HH. Antibiotic susceptibility of bacterial pathogens isolated from the aqueous and vitreous humor in the Antibiotic Resistance Monitoring in Ocular Microorganisms (ARMOR) surveillance study. *J Cataract Refract Surg*. 2016;42(12):1841-1843.
58. Cheng AM, Zhao D, Chen R, et al. Accelerated restoration of ocular surface health in dry eye disease by self-retained cryopreserved amniotic membrane. *Ocul Surf*. 2016;14(1):56-63.
59. Donnenfeld E. LASIK patients benefit from plugs at the time of surgery. *EyeWorld*. <https://www.eyeworld.org/lasik-patients-benefit-plugs-time-surgery>. Published June 2017. Accessed February 23, 2018.
60. Assaad D, Wong D, Mikhail M, et al. Bacterial endophthalmitis: 10-year review of the culture and sensitivity patterns of bacterial isolates. *Can J Ophthalmol*. 2015;50(6):433-437.
61. Shorstein NH, Winthrop KL, Herrinton LJ. Decreased postoperative endophthalmitis rate after institution of intracameral antibiotics in a Northern California eye department. *J Cataract Refract Surg*. 2013;39(1):8-14.
62. Barry P, Seal DV, Gettinby G, et al. ESCRS study of prophylaxis of postoperative endophthalmitis after cataract surgery: preliminary report of principal results from a European multicenter study. *J Cataract Refract Surg*. 2006;32(3):407-410.
63. Witkin AJ, Chang DF, Jumper JM, et al. Vancomycin-associated hemorrhagic occlusive retinal vasculitis: clinical characteristics of 36 eyes. *Ophthalmology*. 2017;124(5):583-595.

FOR INSTANT PROCESSING, COMPLETE THE CME POST TEST ONLINE
[HTTPS://TINYURL.COM/CATARACTANDREFRACTIVECASES](https://tinyurl.com/cataractandrefractivecases)

CME POST TEST QUESTIONS

To obtain *AMA PRA Category 1 Credit™* for this activity, complete the CME Post Test and course evaluation online at <https://www.tinyurl.com/cataractandrefractivecases>. Upon successful completion of the post test and evaluation, you will be able to generate an instant certificate of credit.



See detailed instructions at **To Obtain AMA PRA Category 1 Credit™** on page 3.

1. A 70-year-old male presents for cataract surgery and is diagnosed with moderately severe DED with 2+ MGD. He has elevated tear film osmolarity and 2+ staining in the central and inferior cornea OU; tear break-up time is 5 seconds OU. He is eager to have cataract surgery done soon. What would you use to treat his DED?
 - a. Autologous serum tears
 - b. Self-retaining cryopreserved amniotic membrane
 - c. Topical cyclosporine and punctal plugs
 - d. Topical loteprednol gel, 0.5%, and topical bromfenac, 0.07%
2. A monofocal toric IOL should not be used to correct astigmatism in an eye with:
 - a. Full-thickness corneal graft
 - b. History of hyperopic LASIK
 - c. Glaucoma
 - d. Keratoconus that will require RGP lens wear
3. Watson and colleagues reported that for eyes with keratoconus, use of 43.25 D as a standard K value in IOL power calculations improved refractive outcome predictability if the measured K was:
 - a. < 48 D
 - b. 48 to 55 D
 - c. > 55 D
 - d. Any value
4. Corneal SA in an eye with keratoconus is typically most similar to that in a(n):
 - a. Average cornea
 - b. Posthyperopic LASIK cornea
 - c. Postmyopic LASIK cornea
 - d. Postradial keratotomy cornea
5. What is the noncompliance rate for patients with their glaucoma drops?
 - a. Up to 80%
 - b. Up to 70%
 - c. Between 50% and 70%
 - d. Less than 50%
6. What is the most common cause of endophthalmitis after cataract surgery?
 - a. Coagulase-negative staphylococci
 - b. Methicillin-resistant *S aureus*
 - c. *Pseudomonas* sp.
 - d. *Streptococcus pneumoniae*
7. Which of the following statements is true about cases of vancomycin-associated HORV, as summarized by Witkin and colleagues?
 - a. It had a delayed onset, presenting no earlier than 8 days postoperatively
 - b. It occurred in eyes receiving intracameral or intravitreal vancomycin
 - c. It responded to intravitreal antivascular endothelial growth factor injection
 - d. It occurred only in patients with prior systemic exposure to vancomycin
8. Compared with cataract surgery performed using conventional manual techniques, cataract surgery using a femtosecond laser has been proven to:
 - a. Improve safety in eyes with corneal scarring
 - b. Improve surgical workflow
 - c. Minimize intraoperative miosis risk
 - d. Reduce ultrasound energy use
9. In the diabetic arm of the PREMEDI study, no cases of CME were observed in patients randomized to treatment with:
 - a. Bromfenac and dexamethasone
 - b. Bromfenac, dexamethasone, and intracameral triamcinolone acetonide
 - c. Bromfenac, dexamethasone, and intravitreal bevacizumab
 - d. Bromfenac, dexamethasone, and subconjunctival triamcinolone acetonide
10. A patient with primary open-angle glaucoma, a history of steroid response, and DED is undergoing cataract surgery with a MIGS procedure. How would you manage postoperative inflammation?
 - a. Loteprednol gel, 0.5%, for 4 weeks
 - b. Loteprednol gel, 0.5%, and an NSAID for 4 weeks
 - c. NSAID for 6 weeks
 - d. Prednisolone acetate, 1%, and an NSAID for 4 weeks